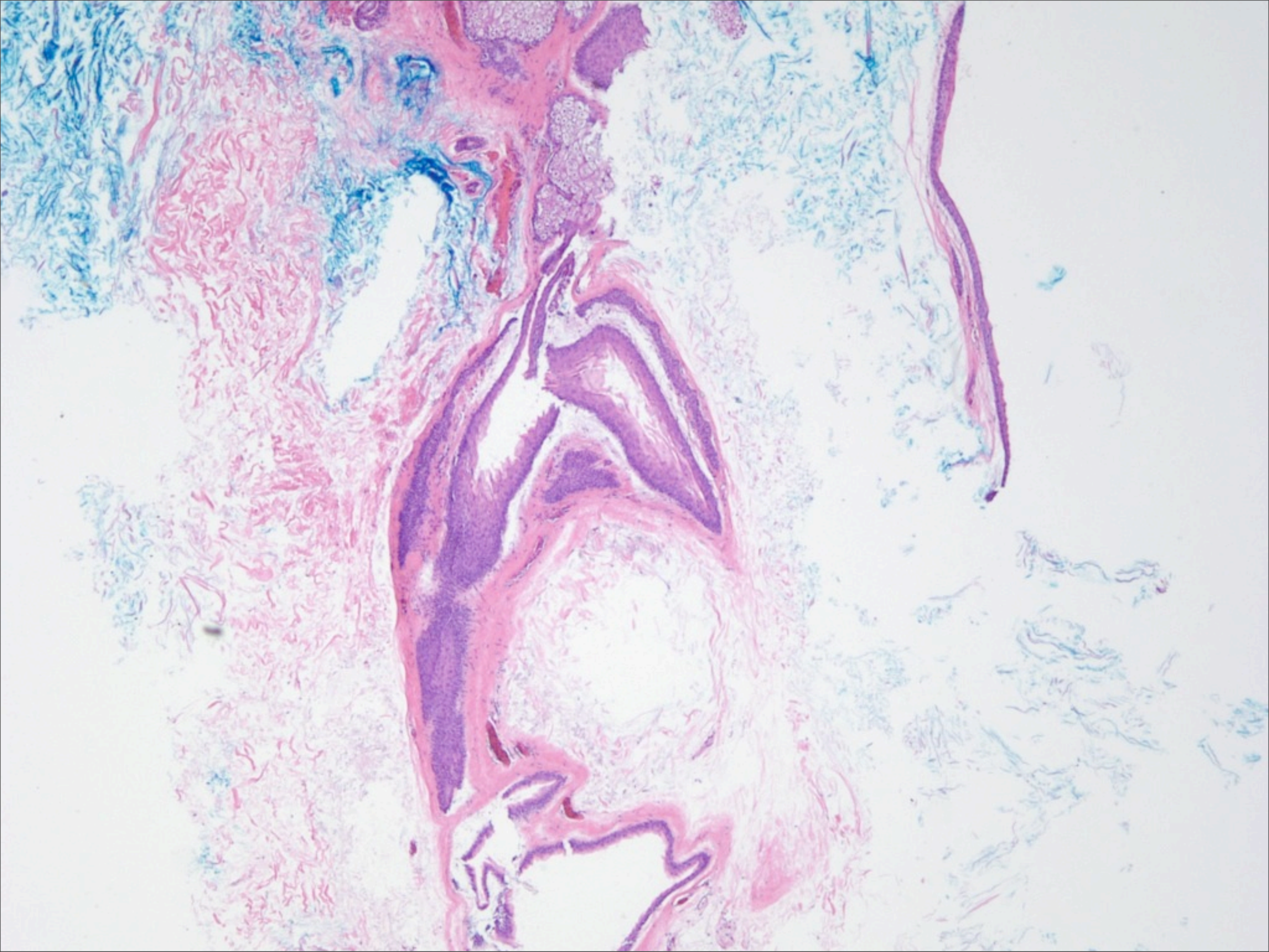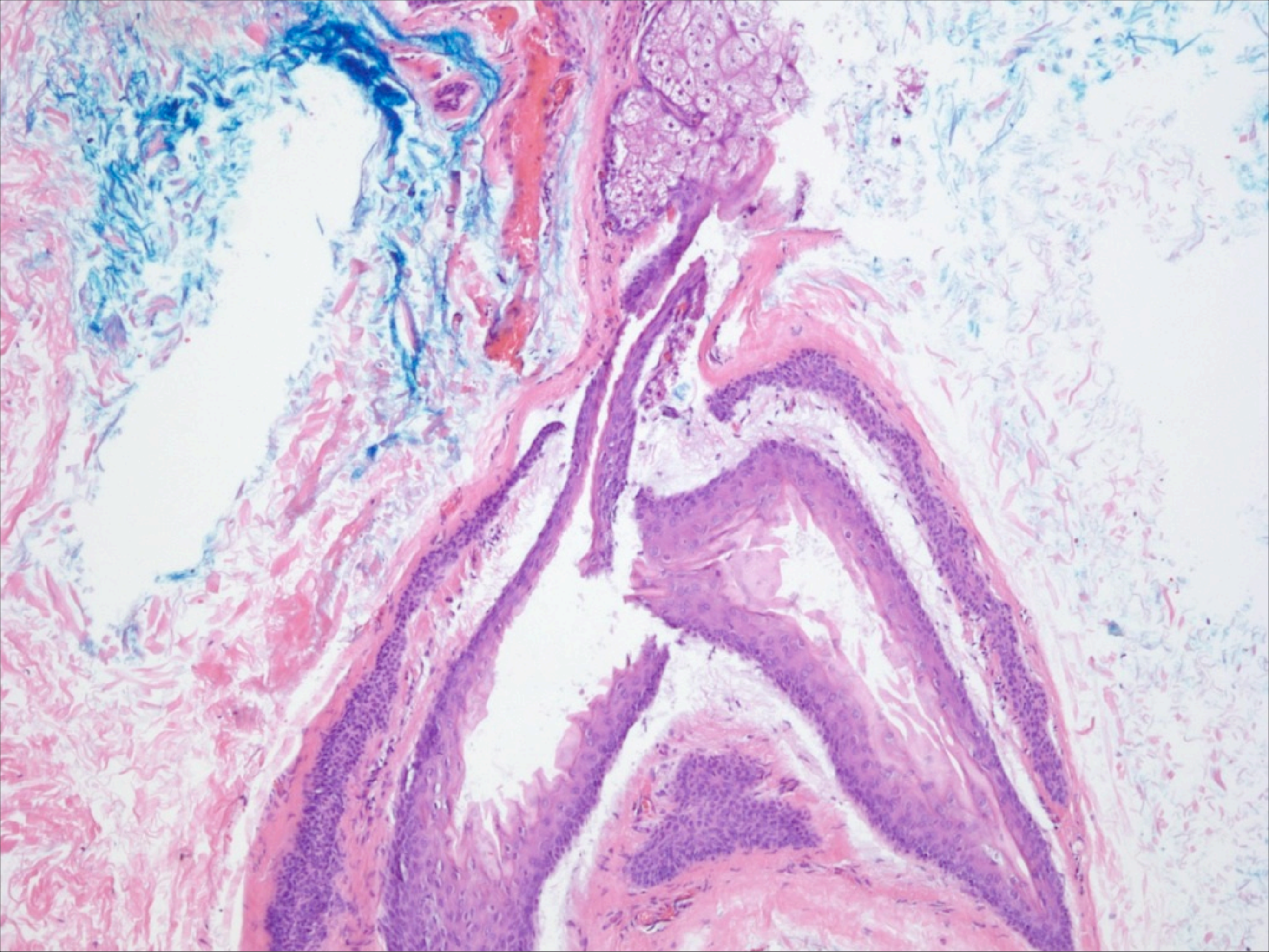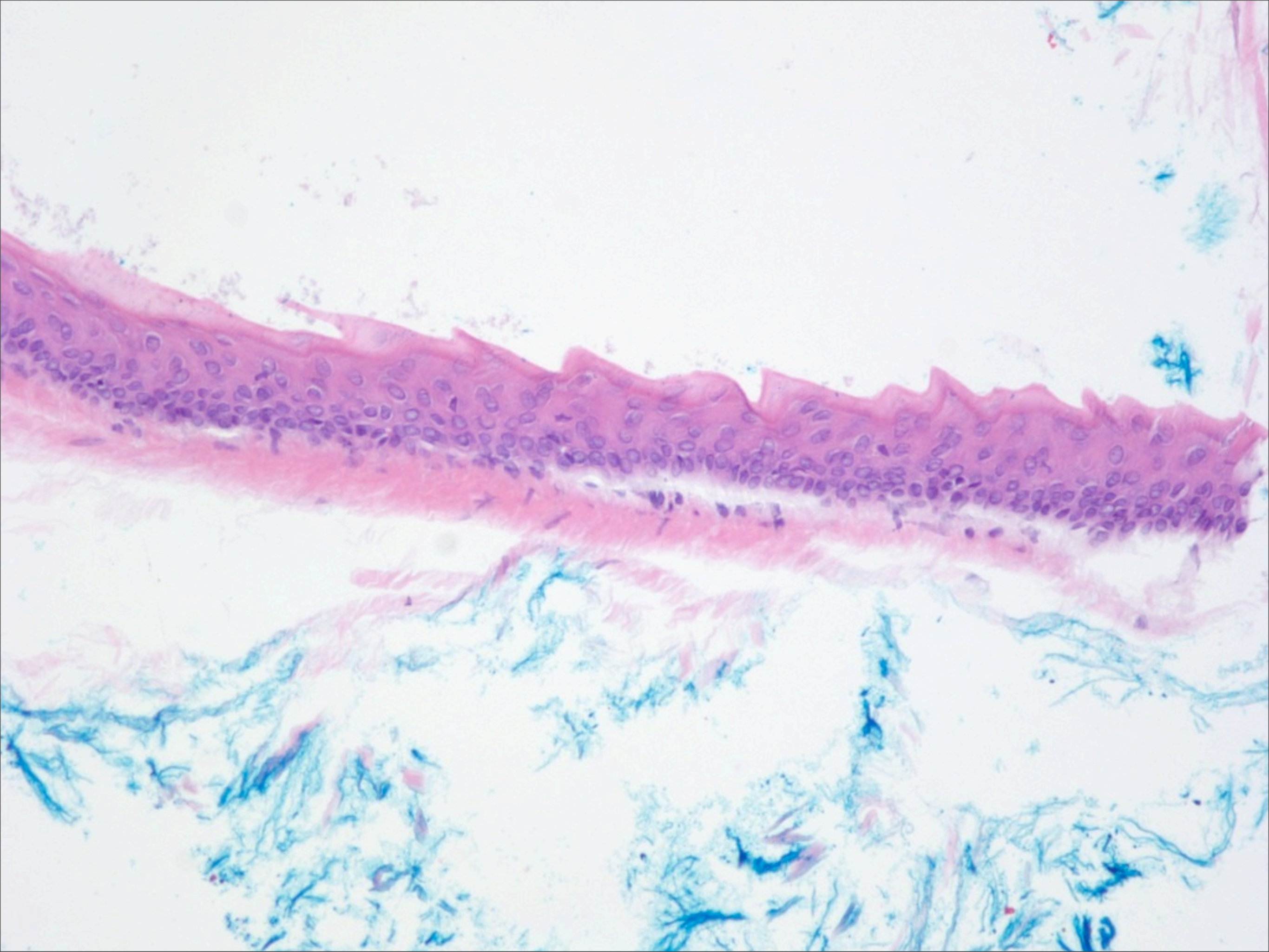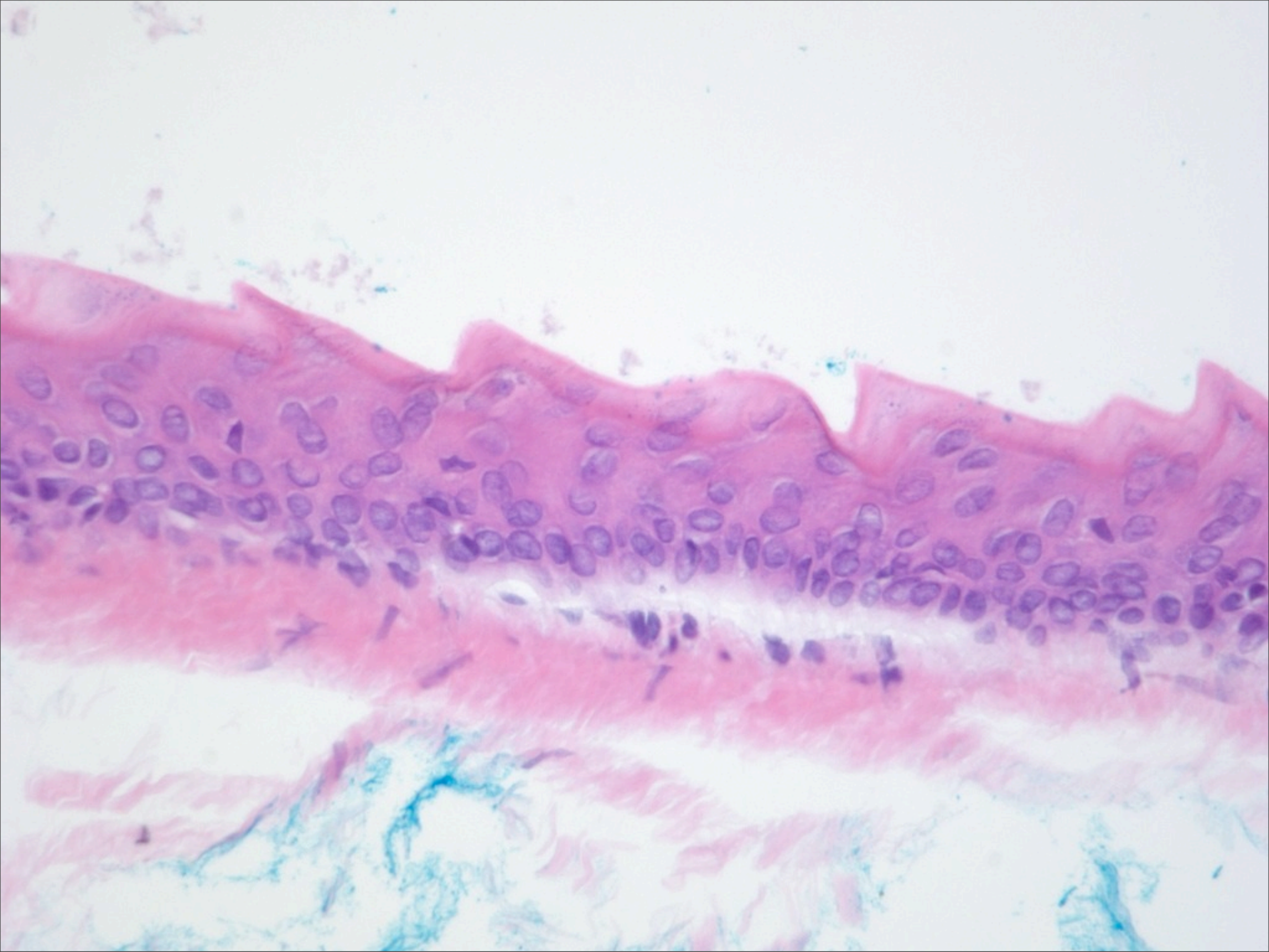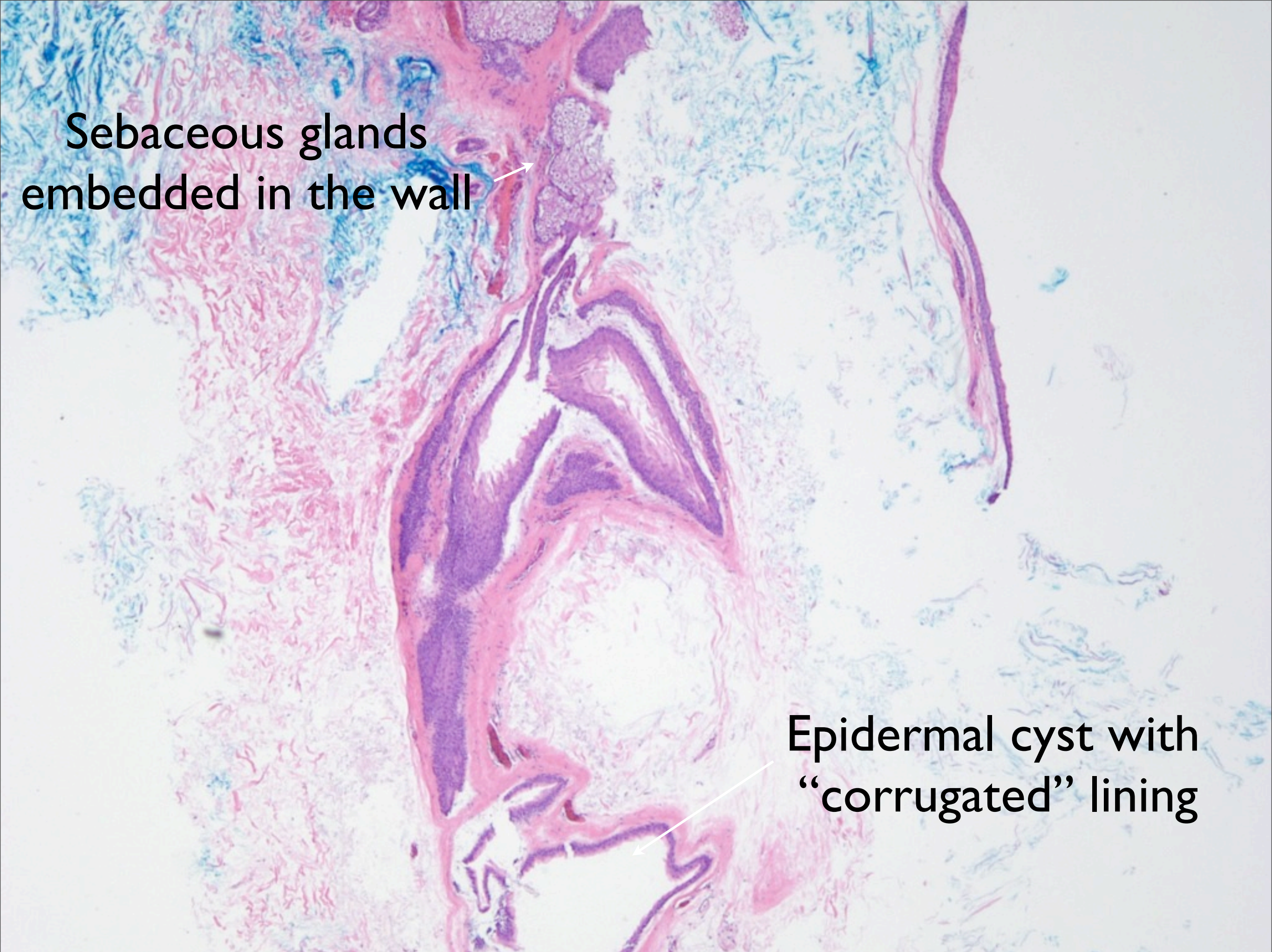


Steatocystoma



Sebaceous glands
embedded in the wall

Epidermal cyst with
“corrugated” lining